CHAPTER V

THE MANTLE

	Page
Appearance	74
Anatomy	74
Rudimentary muscle of the mantle	79
Histology	79
Connective tissue	79
Muscles	83
Blood vessels	84
Epithelium, tentacles, and nerves	84
Periostracal groove and gland	86
Subligamental ridge	89
Functions of the mantle	90
Formation and calcification of shell	91
Theories of calcification	94
Cytological identification of calcium	101
Sources of calcium	103
Mineralogy of calcium carbonate in molluscan shells	103
Rate of calcification	104
Bibliography	107

The inner organs of all mollusks are covered with a soft and fleshy fold of tissue called the mantle or *pallium* (Latin for cloak or coverlet). The structure of the mantle is relatively simple: the organ consists of a sheet of connective tissue containing muscles, blood vessels, and nerves and is covered on both sides by unicellular epithelium. Many blood cells invade and wander throughout the entire thickness of the mantle, infiltrating the spaces (sinuses) in the connective tissue, and crawling through the epithelium to aggregate on the outer surface of the mantle.

Although the principal role of the mantle is the formation of the shell and the secretion of the ligament, the organ plays a major part in several other functions. It receives sensory stimuli and conveys them to the nervous system and assists in the shedding and dispersal of eggs during spawning (see ch. XIV). The mantle also participates in respiration by providing direct exchange of gases between the surface tissues of the oyster and the surrounding water. It stores reserve materials (glycogen and lipids), secretes large quantities of mucus and, finally, aids in excretion by discarding blood cells loaded with waste products.

APPEARANCE

The appearance of the mantle reflects the condition of the oyster. At the time of sexual maturity it is a creamy-yellowish color. In oysters which have accumulated large amounts of glycogen with the onset of the cold season the mantle is white and thick. In oysters of poor quality or in those which have not yet recovered after spawning, the mantle is so transparent that the brown or greenish color of the underlying digestive organ is clearly visible through the thin and watery tissue. Oysters in this condition are particularly suitable for the study of muscles, blood vessels, and nerves which in good quality, "fat" oysters are covered by a thick layer of reserve materials.

Pigment cells are concentrated along the free edge of the mantle and in the tentacles in a band varying in color from light brown to jet black. Also, accumulation of copper in the blood cells may produce a distinct green coloration. Different intensities of pigmentation are often found in oysters of identical origin growing together, and cannot be correlated with geographical location or type of bottom.

ANATOMY

For a detailed study of the mantle the oyster should be fully narcotized by Epsom salt (see p. 65) or by refrigerating it overnight at a temperature of about 2° to 4° C. After the valves are forced apart and the body dissected along the median plane, the two halves of the oyster are left attached to their respective valves and the mantle is preserved in its natural position by having a large quantity of fixing fluid poured over it. Portions of the mantle required for study are cut off, stained, dehydrated, cleared, and mounted. In this way very satisfactory whole mounts can be obtained.

The two lobes of the mantle are joined together at the dorsoposterior margin, and form a cap or hood which covers the mouth and the labial palps (fig. 71). Along the anterior and ventral sides of the body the lobes are free and follow the curvature of the shell. When the oyster opens its shell the mantles separate with the valves to

which they adhere, leaving a narrow opening between the two lobes through which sea water can enter the mantle cavity. The edge of the mantle, may, however, occupy various positions: it may extend parallel and beyond the edge of the valves to leave a wide space between the two opposing lobes, or it may bend inward almost perpendicular to the shell surface (fig. 74) to reduce or completely close the opening between the two lobes and thereby limit the access of water to the mantle cavity. The behavior of the mantle edge as a regulatory mechanism controlling the flow of water through the mollusk will be discussed later (p. 185). In a closed oyster the mantle edge is located about midway between the distal margin of the gills and the edge of the shell. Its position is marked by an impression called the pallial line, which is less pronounced in the oysters than in clams and some other bivalves.

At the ventroposterior end of the body the two opposing lobes of the mantle join the gills to form the delicate outside wall of the cloaca (figs. 72 and 75, cl., f.). On the left side of the body the mantle is joined to the visceral mass; on the right side it is separated from the visceral mass by the promyal chamber. The fusion of the mantle with the visceral mass and with the bases of gill plates forms the wall of the epibranchial chamber, which leads to the cloaca (fig. 75, cl.). The relative position of the epibranchial and promyal chambers can be seen in the cross section of the oyster made through the dorsal part of the body (fig. 73, ep.br.ch.; pr.ch.).

An oblong slit between the two mantle lobes on the dorsoposterior side of the body marks the opening of the promyal chamber. The inside of this chamber can be examined by completely narcotizing the oyster and forcing its valves apart as far as possible without tearing the adductor muscle. Viewed from the posterior side the promyal chamber in a relaxed oyster appears as an oval cavity (fig. 75) to the left of the adductor

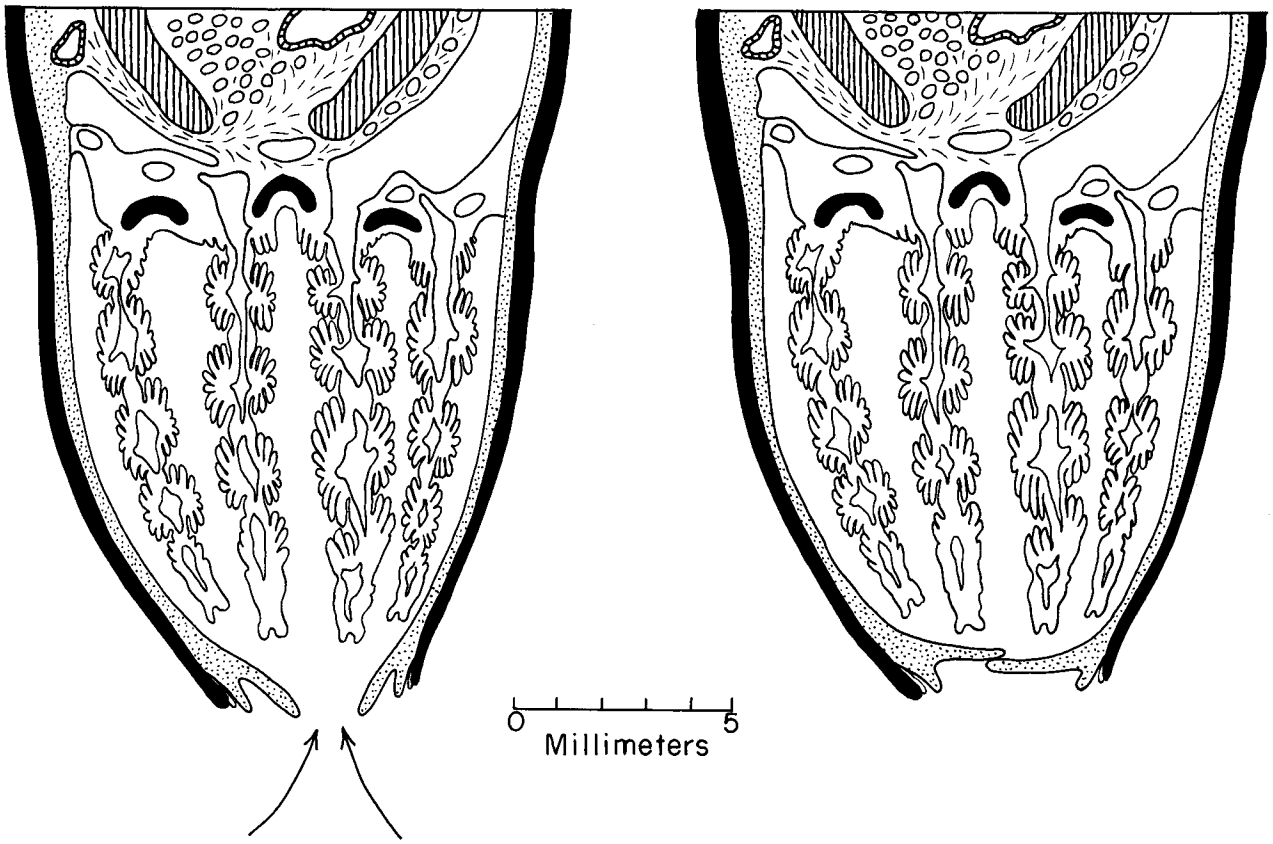

FIGURE 74.—Cross sections of the valves, mantle, gills, and adjacent portion of the visceral mass of *C. virginica*. In both diagrams the valves are open; the open pallial curtain (at left) permits free access of water to the mantle cavity; the closed pallial curtain (at right) prevents water from entering the mantle cavity. The outer lobe adheres closely to the valve and is not visible. Drawn from the photomicrographs of cross section of adult oyster. Bouin, hematoxylin-eosin.

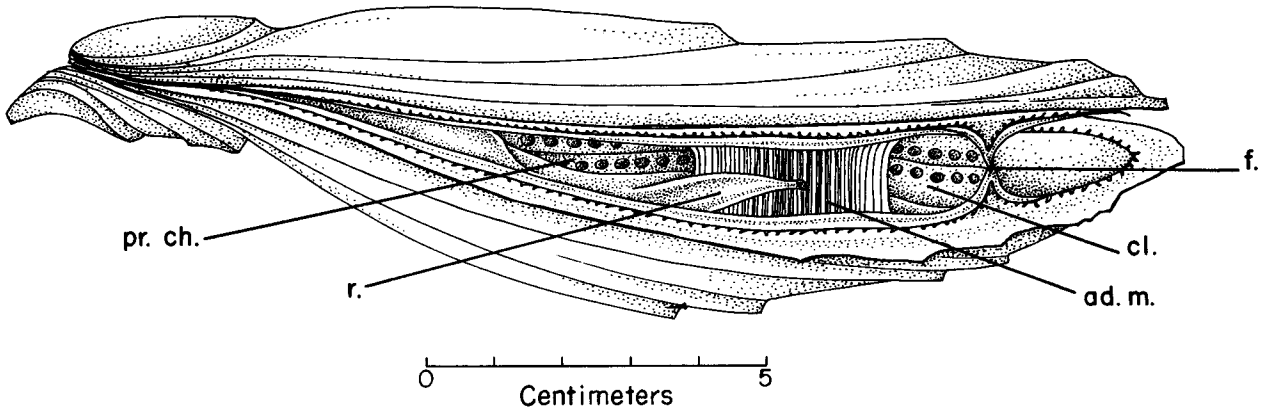

FIGURE 75.—Promyal chamber (at left) and cloaca (at right) viewed from the posterior side of a large oyster (*C. virginica*) completely relaxed by narcosis. Note the fusion of the two opposing lobes of the mantle, and the adductor muscle (in the middle). Drawn from life. Actual size. ad.m.—adductor muscle; cl.—cloaca; f.—fusion of mantle lobes and gills; pr.ch.—promyal chamber; r.—rectum.

muscle. The large round openings of the water tubes of the gills can be seen on the inner wall of the chamber. The rectum extends along the edge of the chamber, ending with a round anus adhering to the side of the adductor muscle; the opening of the cloaca lies to the right of the muscle. The water tubes emptying into the cloaca and the fusion of the mantle with the gill lamellae are also clearly visible.

The most conspicuous components of the mantle are the radial muscles, the blood vessels, and the nerves (fig. 76). All these structures can be identified in a piece of fresh tissue stretched over a glass slide and examined under strong illumination with a low-power microscope. For more detailed study, it is necessary to prepare whole mounts or to section the preserved tissues.

The radial muscles extend from the place of their attachment to the visceral mass to the edge of the mantle. At about two-thirds of their length from their base they begin a fanlike expansion toward the periphery before terminating in the base of the tentacles. The majority of the muscles are accompanied along their length by nerves, blood vessels, and blood sinuses. Much more slender than the radial muscles are the concentric muscular bands which parallel the free edge of the mantle (not shown in fig. 76) and are more abundant at its thickened distal edge.

Because of its strongly developed musculature, the mantle is highly contractile. It may stretch a considerable distance beyond the edge of the valve, or withdraw inside the shell, and even roll up into a tube. Contraction of the radial muscles will throw the inner surface of the mantle into ridges which serve as temporary channels for discarding mucus and foreign particles accumulated on it. These movements may involve either the entire surface of the mantle or only a small portion of it, depending on the intensity of stimulation received by the tentacles.

The wide circumpallial artery (fig. 76, cp.a.) follows the entire periphery of the mantle. At low magnification it is usually visible as a wide tubular structure with many branching vessels which communicate with the irregular spaces (blood sinuses) within the connective tissue. A large pulsating blood vessel, called the accessory heart (ch. XI, fig. 236), is located in the anteroventral part in each lobe of the mantle. The structure and the function of this vessel are discussed in chapter XI, p. 254.

Just outward from the circumpallial artery runs the circumpallial nerve, which also extends along the entire margin of the mantle. In whole mount preparations seen under low power, the circumpallial nerve appears as a compact unbranching band. Examination under high power, however, reveals a fine network of small nerves connecting the circumpallial nerve with nerves and with the visceral and cerebral ganglia. Since nerve fibers on the surface of the mantle and in the tentacles lead to the circumpallial nerve, stimuli received by the neuroreceptors of these areas are transmitted through the circumpallial nerve to the radial nerves and reach either the visceral or the cerebral ganglia.

The thick and muscular border of the mantle is divided into three lobes (fig. 77) which have been described in the literature as "folds" (Awati

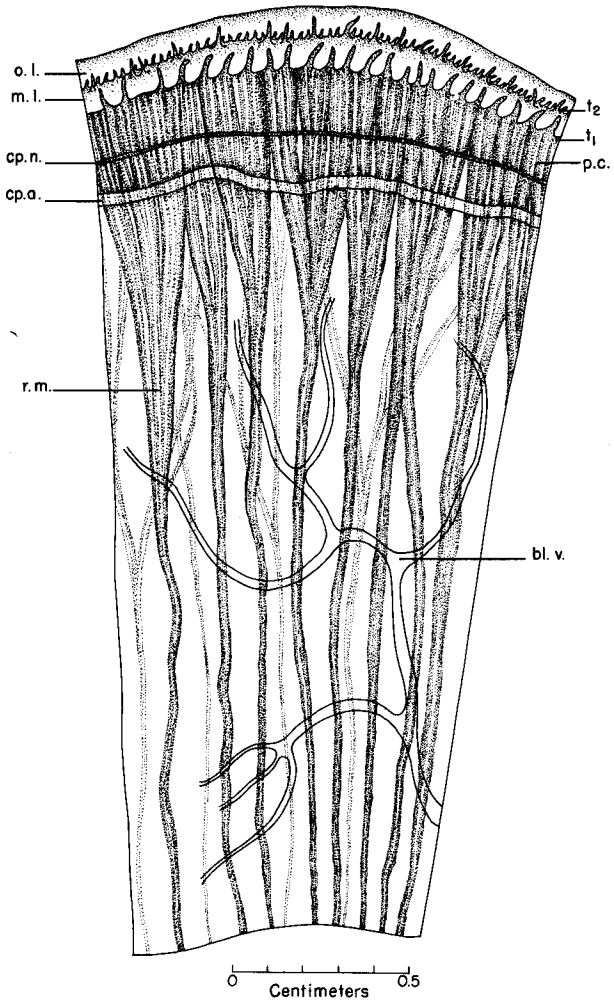

FIGURE 76.—Whole mount of a piece of mantle. Major portion of connective tissue was removed by maceration. Safranin stain. Magnified about 10 times. bl.v.—blood vessels; cp.a.—circumpallial artery; cp.n.— circumpallial nerve; m.l.—middle lobe; p.c.—pallial curtain (inner lobe); r.m.—radial muscle; o.l.—outer lobe or shell lobe; t_1—tentacles of inner lobe; t_2—tentacles of middle lobe. Radial nerves surrounded by radial muscles are not visible. Formalin 5 percent, hematoxylin.

and Rai, 1931), "reduplications" (Nelson, 1938; Pelseneer, 1906), "lamellae" (Hopkins, 1933), "lames" in French (Leenhardt, 1926), and "Klappe", in German (Rawitz, 1888). The term "reduplication" is misleading because the lobes are not formed by the duplication of the mantle tissue, being comparable rather to a fringe or flounce at the margin of a soft material. To avoid confusion the term marginal lobes is retained in this text.

The mantle border of all the species of oysters studied, namely, *C. virginica*, *C. angulata*, *C. gigas*, *O. edulis*, and *O. lurida* is divided into three projecting lobes, the outer or shell lobe (sh.l.), the middle lobe (m.l.), and the inner lobe or pallial curtain (p.c.). Hopkins' statement (1933, p. 483) that "The border of the mantle (of *C. gigas*) divides into two lamellae, each bearing a row of tentacles" is an obvious inaccuracy of description.

The outer or shell lobe (sh.l.) is narrow and devoid of tentacles. It lies in contact with the margin of the shell and may be seen protruding beyond the edge of the valve during periods of rapid growth. The middle and the inner lobes each bear a row of sensitive and highly contractile tentacles.

The inner lobe or pallial curtain (fig. 77, p.c.) is especially broad and turned inward. In describing this structure in scallops Pelseneer named it the "velum" (1906). Although that term has been used by several investigators (Awati and Rai, 1931; Dakin, 1909b) Nelson (1938) pointed out that the term "velum" is better known as the swimming organ of the pelecypod larvae and proposed to call the inner lobes of the mantle the "pallial curtains". This term seems to be appropriate, but is used in this book in the singular since there appears to be no advantage in the plural recommended by Nelson.

The inner lobe may be projected into the mantle cavity (fig. 74). Depending on the degree of contraction of various sets of muscles the inner lobe assumes different angles in relation to the mantle as a whole. In a fully relaxed mollusk the lobe of each side extends outward in the general plane of the mantle and shell. In a contracted state the lobes on both sides project inward almost at right angles to the surface of the mantle; in this position the mantle borders touch and the tentacles of the two sides interlock, effectively sealing the entrance to the mantle cavity. This function of the inner lobe was first described by Rawitz in 1888 and was redescribed in 1933 by Hopkins. As will be shown later (p. 304) the pallial curtain also plays an important role during the spawning of female oysters.

The deep furrow between the shell lobe and the middle lobe is called the periostracal groove (fig. 77, per.gr.), the name referring to the secretion site of organic shell material by glandular cells concentrated in the deepest portion of the groove and collectively known as the periostracal or conchiolin gland (c.gl). During the shell-

733-851 O—64——6

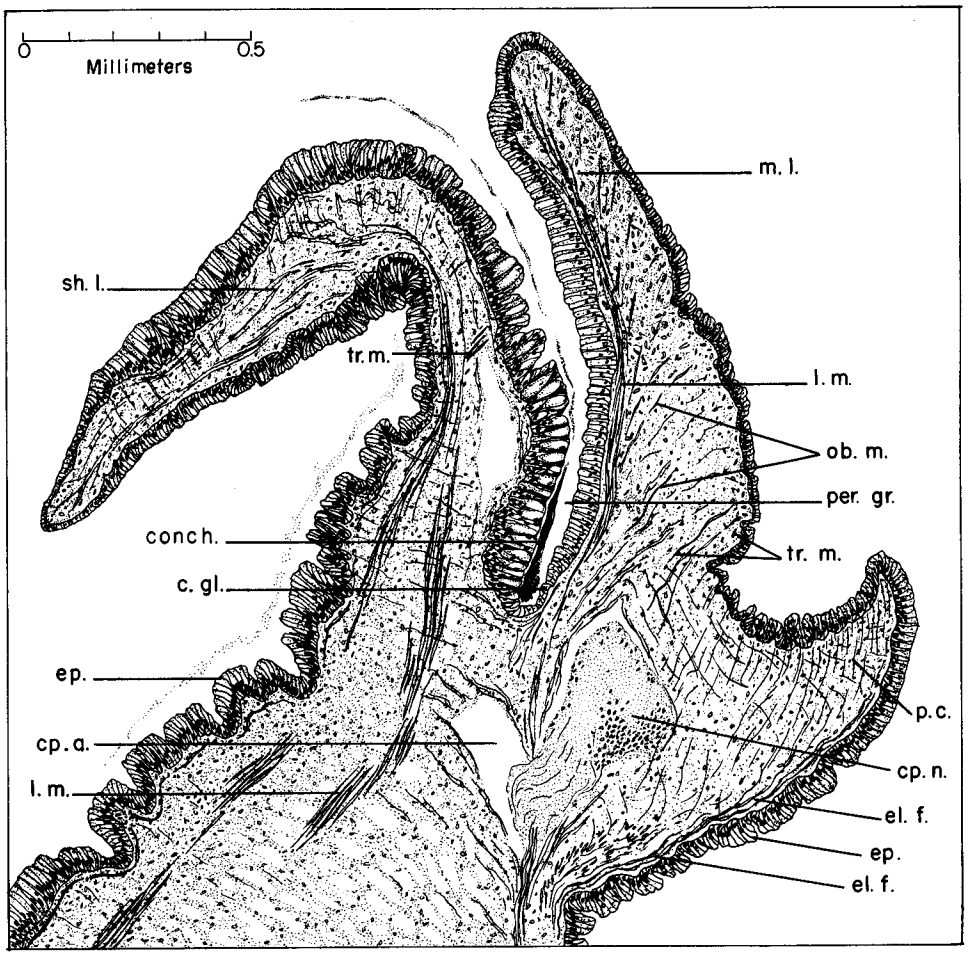

FIGURE 77.—Transverse section of the edge of the mantle of adult *C. virginica*. Bouin 3, hematoxylin-eosin. The outer or shell lobe at left faces the valve (not shown) and is bent as a result of fixation. The section passes between the tentacles of the inner lobe (pallial curtain); only the tentacle of the middle lobe (m.l.) is seen. c.gl.—conchiolin (or periostracal) gland; conch.—sheet of conchiolin spread over the shell lobe; cp.a.—circumpallial artery; cp.n.—circumpallial nerve; el.f.—elastic fibers; ep.—epithelium; l.m.—longitudinal muscles of tentacles; m.l.—middle lobe; ob.m.—oblique muscles; p.c.—pallial curtain (inner lobe); per. gr.—periostracal groove; sh.l.—shell or outer lobe; tr.m.—transverse muscles.

growing season, viscous yellowish material (fig. 77, conch.) accumulates in the groove and gradually oozes out to the periphery of the outer mantle lobe, where it solidifies into the periostracum. The groove between the middle lobe (m.l.) and the pallial curtain secretes mucus, which is gradually moved by ciliary currents to the outer margin of the mantle and there discarded.

It has already been noted that the edges of the middle and the inner lobe each bear a row of highly extensible, tapering tentacles; however, their arrangement and size in the two lobes are different. Two types are clearly visible along the edge of the middle lobe: numerous short and slender tentacles, and less abundant long and stout ones (fig. 76). The order of the tentacles follows a certain pattern, namely, each long tentacle is succeeded by a group of four to six small ones (t_2). The stout tentacles frequently occupy a position slightly out of line with the small ones, being a little nearer to the inner fold. The inner lobe bears only the long and stout tentacles (t_1).

There is great variation in the size of all the tentacles and in their pigmentation. Since they are highly sensitive to touch and other stimuli and retract at the slightest disturbance, their relative size can be observed only when they are completely relaxed. In fully narcotized adult oysters the ratio between the numbers of tentacles on the

inner and middle lobes was found to vary from 10:18 to 10:32.

It has not yet been definitely established whether the two types of tentacles contain different receptors and therefore respond to different stimuli. According to Elsey (1935) the large tentacles of *C. gigas* are more sensitive to hydrochloric acid than the small ones. Hopkins (1932) does not specify which row of tentacles was under observation in his work on sensory stimulation of *C. virginica*. In my experiments (see p. 293) observations were made exclusively on the long tentacles of the inner lobe.

A narrow and slightly pigmented cylindrical structure along the dorsal edge of the mantle (fig. 78) marks the position of the subligamental ridge, the organ which secretes the ligament. The ridge consists of a layer of specialized epithelium underlined by connective tissue. Large blood vessels are found close to the base of the ridge. Microscopic structure of the ridge is given on p. 83.

RUDIMENTARY MUSCLE OF THE MANTLE

A small and sometimes hardly visible muscle is located on the dorsal part of the mantle. Its location is sometimes marked by light violet pigmentation and by a shallow depression in the corresponding part of the valve to which the muscle adheres. The attachment is weak, and in the majority of oysters the muscle separates from the valve when the valve is lifted. Leenhardt (1926) states, however, that in some *O. edulis* the muscles were so strongly attached to the shell that they could not be separated without rupturing the mantle tissue. Examination of sections of the mantle of *C. virginica* from the Woods Hole area convinced me that muscle fibers do not extend from one side to the other, but end in the connective tissue of the mantle. The muscle is apparently nonfunctional and morphologically is not analogous to the anterior adductor of bivalves. Leenhardt (1926) considers the rudimentary muscle of the mantle as a vestige of the larval foot retractor which disappears during metamorphosis. Stenzel (1963) states that this muscle is present in all the Ostreidae and calls it Quenstedt's muscle in honor of its discoverer (Quenstedt, 1867).

HISTOLOGY

The mantle consists of connective tissue which envelops the muscles, blood vessels, and nerves and is covered on both sides with the epithelium.

CONNECTIVE TISSUE

The most conspicuous structural element of the connective tissue is the vesicular cell, characterized by large globular or oval body and relatively small nucleus without nucleoli. In zoological literature these cells appear under a variety of names and were even incorrectly considered as lacunae (Leenhardt, 1926) and mucus cells (List, 1902). Well-developed membranes outline cell boundaries sharply; the protoplasm within forms a delicate network of fine granules. In preparations dehydrated with alcohol the inside of the vesicular cells appears almost empty, but in tissues treated with osmic acid and in frozen sections stained with Sudan II and other fat stains large globules of lipids are seen to fill the inside of the cells (figs. 79 and 80). Less abundant are the smaller round cells with more compact protoplasm. They often occur near small arteries (fig. 81, r.c.). The fusiform cells (f.c.) with small bodies and oval nuclei form long branching processes which anastomose and touch each other.

Examination of frozen sections of connective tissue treated with toluidine blue or other metachromatic stains shows clearly the presence of a cytoplasmic ground substance with a very fine reticulum supporting various inclusions. After the removal of glycogen this substance can be stained very deeply with periodic acid fuchsin (McMannus reagent)or with Hale stain which is used to test for acid polysaccharides of the hyaluronic acid type (Hale, 1946). The results of such staining reactions have been interpreted in the literature as indicating the presence of mucopolysaccharides or mucoproteins. Histological methods are not entirely dependable (Meyer, 1957), but so far no chemical analyses of the connective tissue of the mantle have been made. It is known, however, that acid mucopolysaccharides are among the components of the ground substances in mammalian tissues. It is very likely tnat they are also present in the connective tissue of the oyster.

Elastic fibrils are scattered throughout the connective tissue of the entire thickness of the mantle but appear to be more abundant at the free edge and in the layers underlying the surface epithelium (fig. 77, el.f.). Muscle fibers are also very abundant and will be discussed in detail later.

In some specimens the mantle may be thin and transparent whereas in others it is thick and

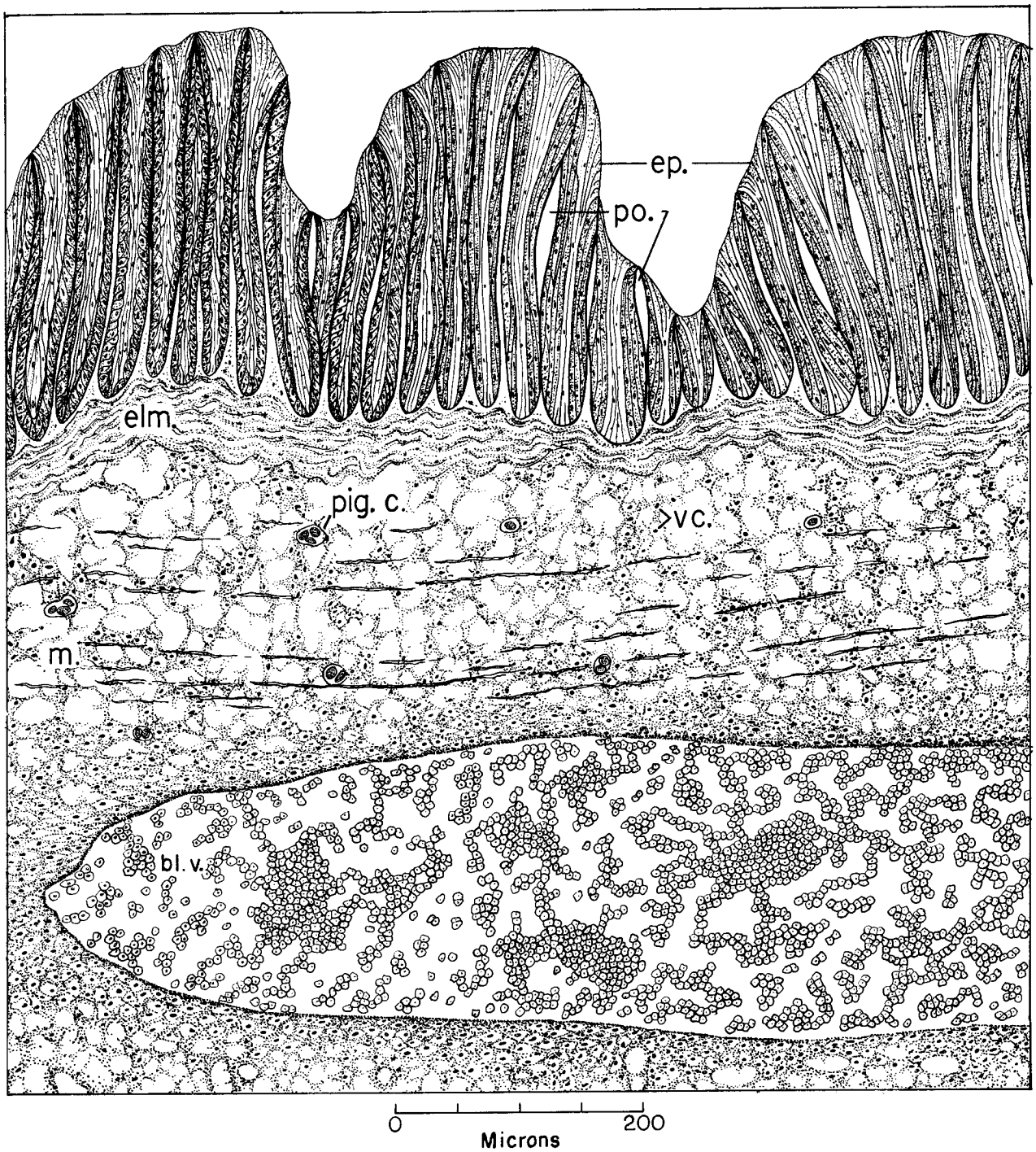

FIGURE 78.—Longitudinal section of the subligamental ridge made at right angles to its dorsal surface. Bouin 3, hematoxylin-eosin. bl.v.—large blood vessel; el.m.—basal elastic membrane; ep.—epithelium; m.—muscle fibers; pig.c.—pigment cells; po.—pockets between the epithelial cells; v.c.—vesicular cells.

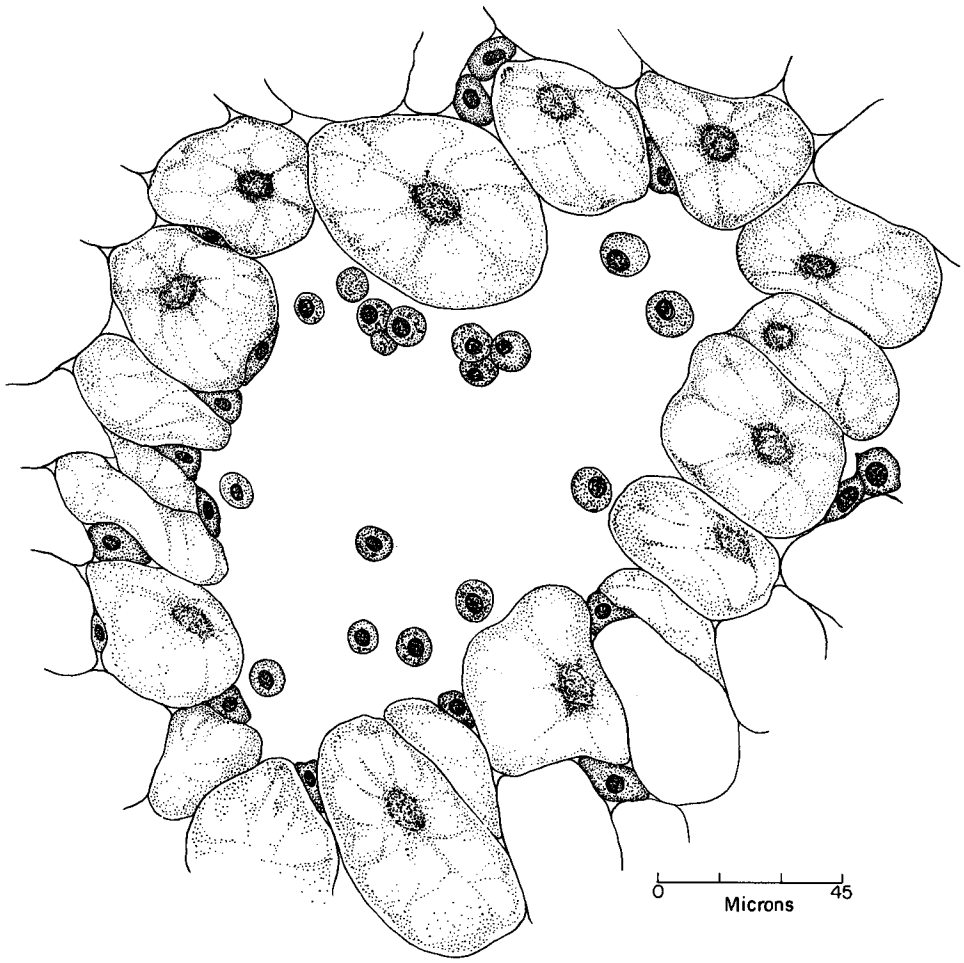

FIGURE 79.—Vesicular cells of connective tissue from the mantle of an adult *C. virginica* surrounding the blood sinus. Blood cells crawl between the cells of connective tissue and penetrate into the sinus. Bouin 3, hematoxylin-eosin.

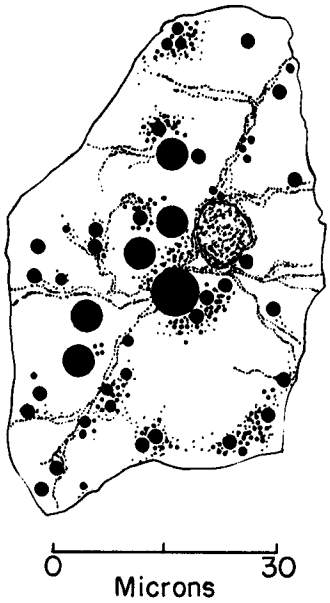

FIGURE 80.—Vesicular cell of connective tissue with fat globules. Frozen section. Sudan II.

opaque. These changes in appearance usually coincide with seasonal cycles in the glycogen content of the connective tissue and with the progressive stages of gonad development.

The presence of glycogen can be easily demonstrated by treating the tissue with Lugol solution (1 percent iodine in 2 percent potassium iodide in water). Specific reagents used for the identification of glycogen, such as Best's carmine and Bensley's modification of Bauer-Feulgen reagent (which stains glycogen granules red-violet), also give good results.

In the live oyster glycogen can be seen as small colloidal granules which ooze from the tissue under slight pressure. In preserved and stained material it appears in the form of granules or rods (fig. 82). The total amount of glycogen in the connective tissue may be so great that the blood vessels and nerves of the mantle are completely hidden under it and cannot be traced by

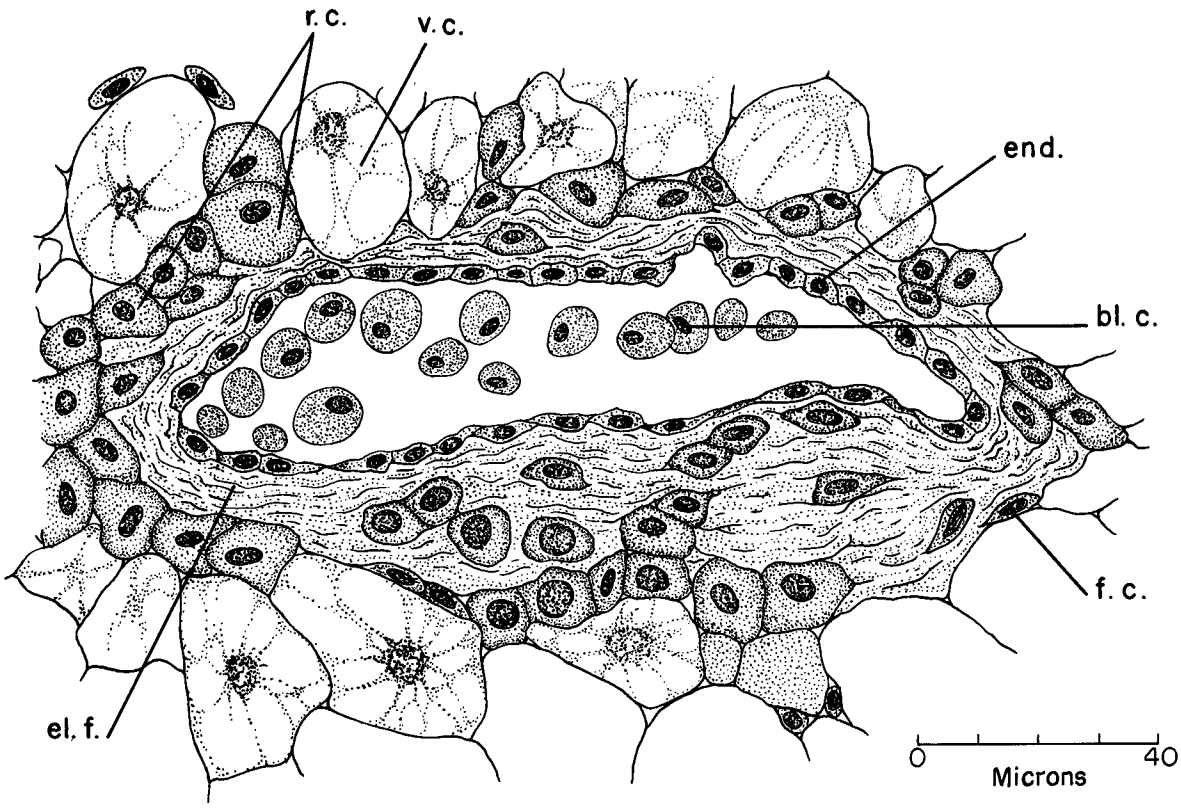

FIGURE 81.—Cross section of a small artery of the mantle. bl.c.—blood cells; e.lf.—elastic fibrils; end.—endothelium; f.c.—fusiform cells; r.c.—round cells; v.c.—vesicular cells. Kahle, hematoxylin-eosin.

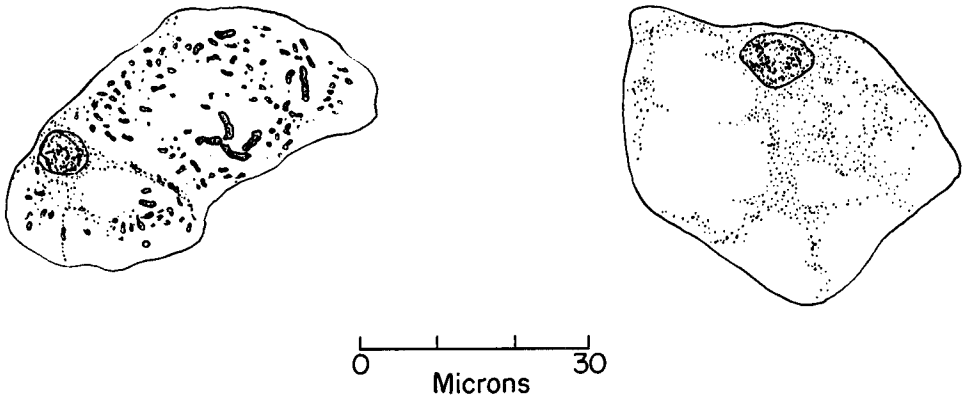

FIGURE 82.—Two vesicular cells from the mantel of an adult *C. virginica*. Left—the cell contains glycogen stained with Best's carmine; fat globules were dissolved in processing. Right—similar cell after fixation with Bouin 3; note complete absence of glycogen and fat, both dissolved during fixation and dehydration.

dissection. Such abundance of reserve material led one of the earlier investigators (Creighton, 1896, 1899) to conclude that its storage in the connective tissue of lamellibranchs is a special adaptation comparable to the storage of fat in the connective tissues of vertebrates.

The quantity of glycogen stored in connective tissue gradually decreases as the gonads of the oyster increase in bulk. This was first reported for *O. edulis* by Pekelharing (1901) and confirmed by the more recent investigations of Bargeton (1942). Evidence presented in the latter work strongly suggests that the growing sex cells utilize the glycogen stored in the vesicular cells surrounding the gonad tubules, but cytological details of this process are still unknown and the problem

has not yet been studied from a biochemical point of view.

After the disappearance of their contained glycogen the vesicular cells do not shrink or collapse. A hypothesis was therefore advanced (Semichon, 1932) that the glycogen granules are supported by a framework of a special substance which remains intact after the dissolution of glycogen. It is claimed that this framework can be revealed by staining with black anilin inks. The evidence for the existence of such a special substance is not, however, convincing. In cells with a moderate content of glycogen the latter can be seen in close contact with the protoplasmic network typical for vesicular cells. Furthermore, the walls of the vesicular cells are fairly rigid and the cells retain their shape even when they are empty. The shrinkage of connective tissue frequently caused by changes in osmotic pressure when the salinity of the water surrounding the oyster is suddenly increased is not associated with the disappearance of glycogen.

The fat globules in vesicular cells vary greatly in size and number, usually forming distinct vacuoles that are easily dislodged. The relationship between the fat and glycogen content of the oyster and the role of lipids in the physiology of lamellibranchs have not been studied.

Large oval cells containing a brown pigment are scattered throughout the connective tissue of the mantle. The pigment is not soluble either in acids or fat solvents. Its chemical nature and physiological significance are not known.

Wandering blood cells are commonly seen in the mantle. They crawl between the connective tissue cells, aggregate in the vicinity of blood vessels and blood sinuses (fig. 79), and are gradually discarded through the surface of the mantle. As a rule, the oyster continually loses a certain amount of blood by diapedesis or bleeding. Any excess of heavy metals accumulated by blood cells (see p. 390) is also discarded by this normal process.

MUSCLES

The radial muscles consist of large, regularly spaced bands of fibers which extend almost the entire width of the mantle from the line of its fusion with the visceral mass and with the adductor muscle to the free margin. For a study of the anatomy of the muscular system the connective tissue in which the bands are firmly enclosed should be macerated in 1 percent potassium hydroxide for about 24 hours. After being washed in distilled water the loosened tissues are removed with a small stiff brush and fine forceps.

The radial muscle bands are composed of large bundles of unstriated fibers which begin to branch toward the distal edge of the mantle about one-third of the distance from that edge. At this level the muscles appear fanlike and enter into all three lobes, where they terminate.

The central part of a muscle band is usually occupied by one or two radial nerves, although muscles without a central nerve (figs. 83 and 84) do occur.

The contraction of the radial muscles pulls the entire mantle inside and throws its surface into ridges. Such a general reaction usually precedes the contraction of the adductor muscle and the closing of the valves. The contraction may occur spontaneously in response to some internal stimulus or it may develop as a result of external irritation produced by chemicals, mechanical and electrical shock, or sudden change in illumination. In response to a weak outside stimulus only a small sector of the mantle contracts, making a slight V-shaped indentation along its periphery. This response may or may not be followed by contraction of the adductor muscle. Strong stimuli, as a rule, result in complete withdrawal of the mantle, contraction of the adductor muscle, and closing of the valves. Besides the large radial bands there are many smaller bundles of transverse fibers (fig. 77, tr.m.) extending diagonally across the thickness of the mantle, a well-developed system of longitudinal muscles (l.m.), and the oblique muscles (ob.m.) of the tentacles.

The longitudinal or concentric muscles follow the general outlines of the edge. They are more abundant at the thickened distal edge of the mantle but do not exhibit the definite pattern of distribution apparent in the radial muscles. The transverse muscle fibers are more numerous in the pallial curtain (fig. 77, tr.m.) than in the other parts of the mantle. They are so arranged that the position of the curtain may be quickly changed in response to external or internal stimuli.

All the muscle cells are of the smooth, nonstriated type with typical elongated nuclei. In some bivalves the muscle fibers of the mantle appear to show a double oblique striation; this was shown to be an optical effect created by a series of fine fibrillae spiralling around the larger fibers (Fol, 1888; Marceau, 1904). Muscle fibers

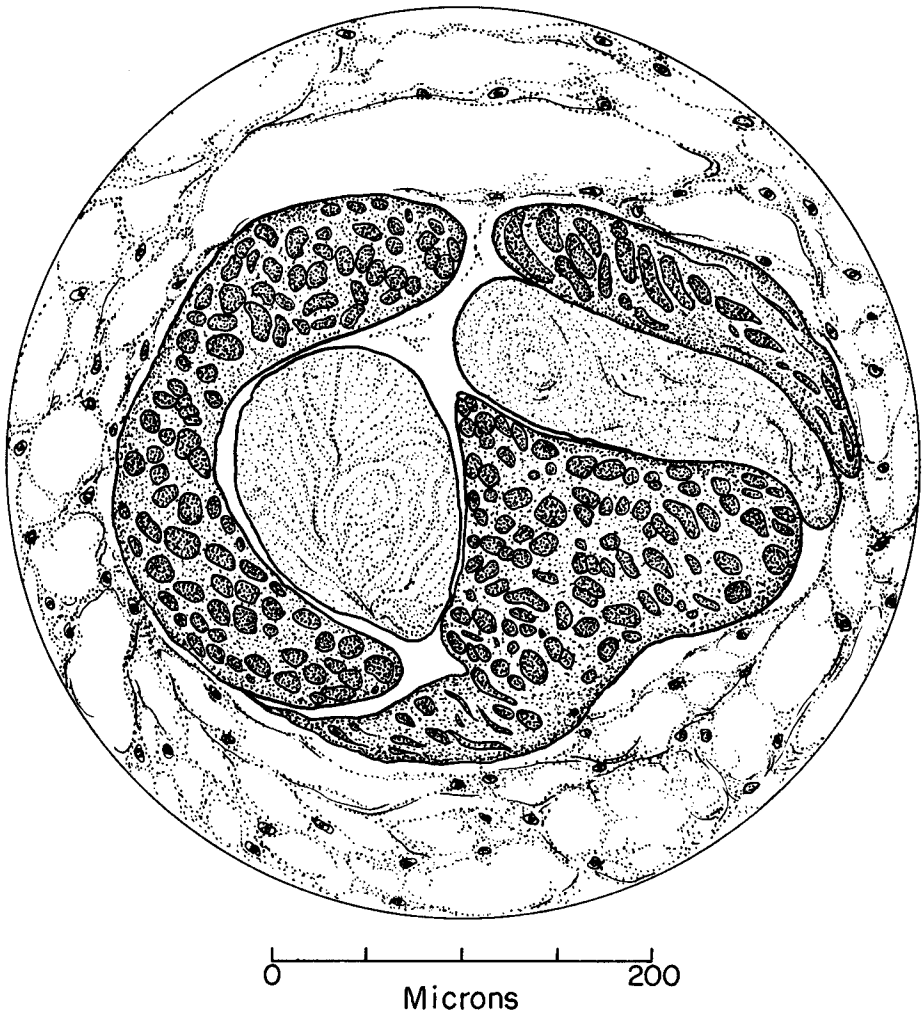

FIGURE 83.—Cross section of the radial muscle of the mantle of an adult *C. virginica*. The muscle completely surrounds two nerves. Bouin 3, hematoxylin-eosin.

with true transverse striation, described in the mantle of *Pecten jacobaeus* and *P. opercularis* (Dakin, 1909a), are not found in the oyster mantle.

BLOOD VESSELS

The principal blood vessels of the mantle (fig. 232 in ch. XI) are the circumpallial artery (cr.p.a.), which runs along its entire periphery and sends out many branches; the common pallial artery (co.p.a.); and a large pulsating vessel in the anteroventral part of the mantle called the accessory heart (fig. 236 in ch. XI). The latter can be observed by dissecting the wall of the epibranchial chamber and spreading the cut tissues apart. The structure and function of these vessels are discussed on page 253.

The small arteries and veins of the mantle can be recognized easily by their histological characteristics. The walls of the arteries have a thick, elastic, muscular layer lined with endothelium (fig. 81, end.). In the veins the elastic layer is much less developed and the endothelium absent (fig. 85). The sinuses (fig. 79) are irregularly shaped spaces in the connective tissue. Since they have no walls of their own they cannot contract. The size of the opening or lumen may be reduced by growth of the surrounding vesicular cells and by accumulation of blood cells.

EPITHELIUM, TENTACLES, AND NERVES

Both sides of the mantle are covered by cylindrical epithelial cells set on an elastic basal membrane (fig. 77). Large goblet cells which secrete mucus and cells containing eosinophile granules are abundant on both sides of the mantle. The cells of the side facing the pallial cavity are long

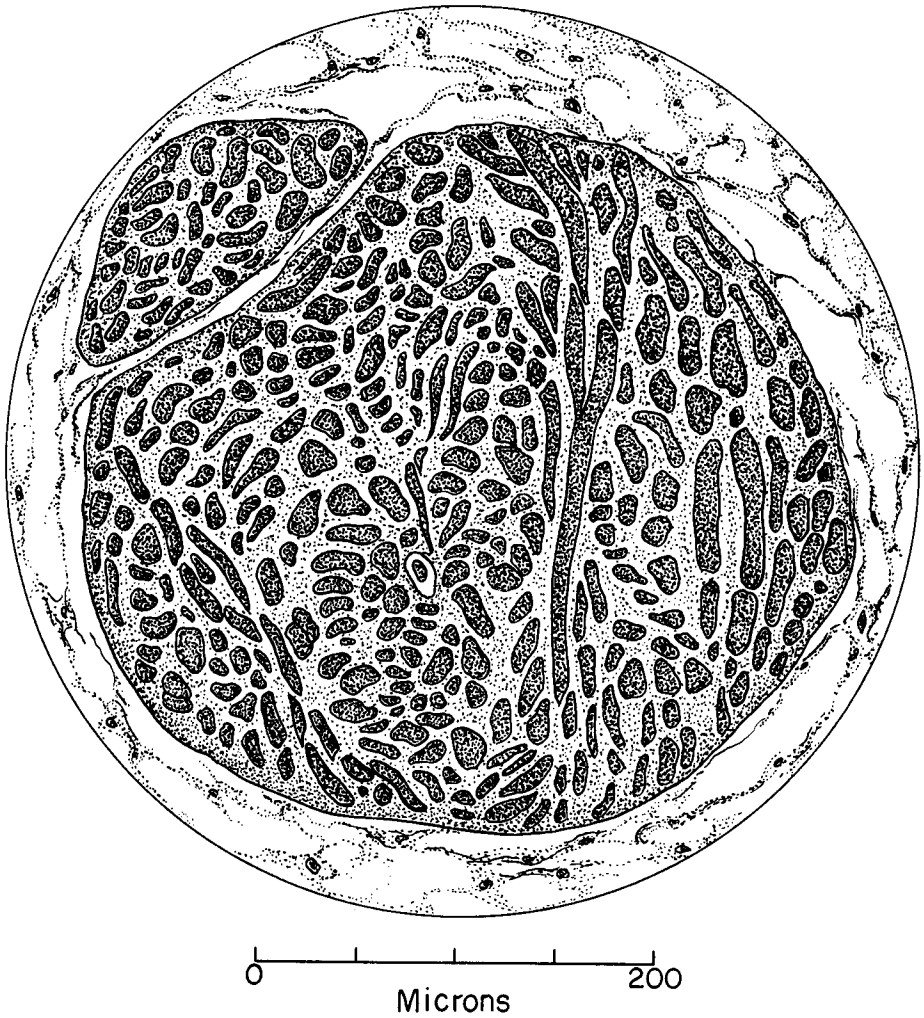

FIGURE 84. Cross section of the radial muscle of an adult *C. virginica*. The muscle is not accompanied by nerve. Bouin 3, hematoxylin-eosin.

and ciliated; those on the outside under the valves bear no cilia and are much shorter, in places almost cubical.

The two sides of the mantle perform different functions. The inner side maintains ciliary currents, which in general move from the base of the mantle to its edge and carry mucus and sediments settled from the water; this material is passed to the margin of the shell to be discharged. The epithelium of the outer side secretes the inner layer of the shell, the so-called calcito-ostracum.

Although the ciliated epithelium of the edge of the mantle contains the same kind and proportion of cellular elements found in other parts of the organ, the cilia at the border of the mantle are especially powerful. The tentacles themselves consist of a core of connective tissue with associated blood vessels, elastic fibrils, and muscle fibers which emerge from branches of the radial muscles. On the outside the tentacles are covered with a single layer of ciliated epithelium to which black or brown pigment imparts a dark color. Special sense organs are absent but the tentacles, especially the long ones, are well supplied with nerves branching out from the nerve which enters the base of the tentacle and is itself connected with the nervous system of the mantle (fig. 86).

The circumpallial nerve provides communication between the tentacles and the radial nerves. The structure of this nerve resembles that of a ganglion: numerous nerve cells of the types found in visceral and other ganglia (see p. 288) occupy the periphery of the nerve; its center consists of nerve bundles with occasional small ganglion cells.

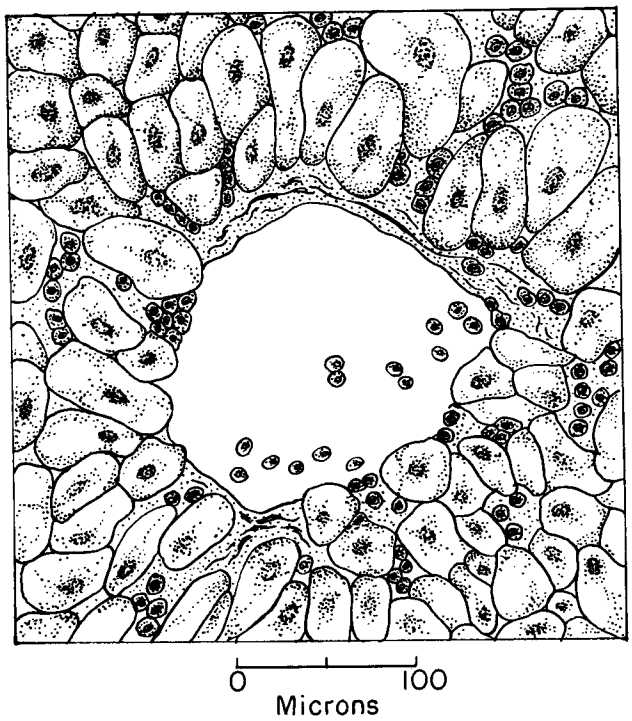

FIGURE 85.—Transverse section of a small vein of the mantle. Note the absence of endothelium and poorly developed elastic layer. Bouin, hematoxylin-eosin.

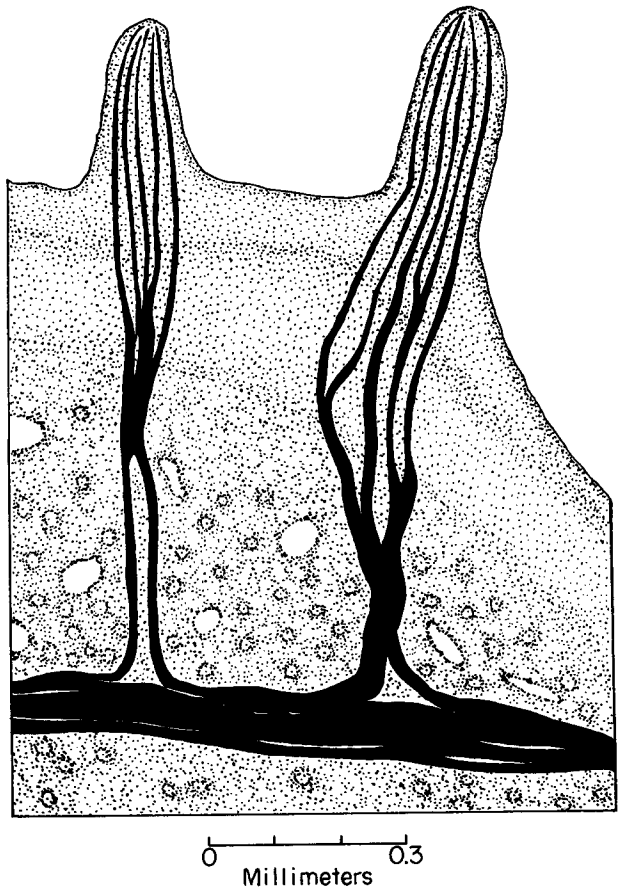

FIGURE 86.—Innervation of the tentacles of the middle lobe. Formalin 5 percent, gold impregnation. Whole mount.

Close nerve contact between the muscles and other organs of the mantle is maintained through a fine nerve network which can be made visible by using the gold impregnation method (fig. 87). I have had no success in revealing it with vital stains.

PERIOSTRACAL GROOVE AND GLAND

The narrow space between the middle and the outer lobes of the mantle edge, called the periostracal groove (fig. 77, per.gr.), is lined with ciliated epithelium which is replaced at the bottom of the groove by glandular cells. The innermost part of the groove is called the periostracal gland (fig. 88), although it would have been more appropriate to refer to it not as a gland but as a secretory epithelial surface (Maximow and Bloom, 1930). This surface is covered with a single layer of glandular cells different in appearance and structure from the epithelial cells of the distal part of the groove. Unlike a true gland, it does not form a compact body extending under the surface of the groove and it has no duct. On transverse sections of the mantle edge the gland sometimes appears as a round structure surrounded by connective tissue. Examination of a series of sections shows, however, that this appearance is caused by the invaginations of the inner surface of the lobe. The periostracal gland is present in all lamellibranchs and was the object of many histological studies (Leenhardt, 1926; List, 1902; Moynier de Villepoix, 1895; Rassbach, 1912; Rawitz, 1888).

There is a conspicuous difference in the appearance of the cells along the two sides of the groove. Those lining the outer lobe (fig. 88, left side) are distended at the distal ends and taper toward the base into slender rootlike processes which, according to Rawitz (1888) who described them in the oyster, penetrate the underlying connective tissue. I was not able to reveal such rootlets in my material. None of these cells bear cilia, although the distal part of the groove, not shown in figure 88, is lined with ciliated epithelium. Typical goblet cells containing eosinophile granules, amoebocytes, and round mucus cells are present in the epithelial layer of both sides of the groove.

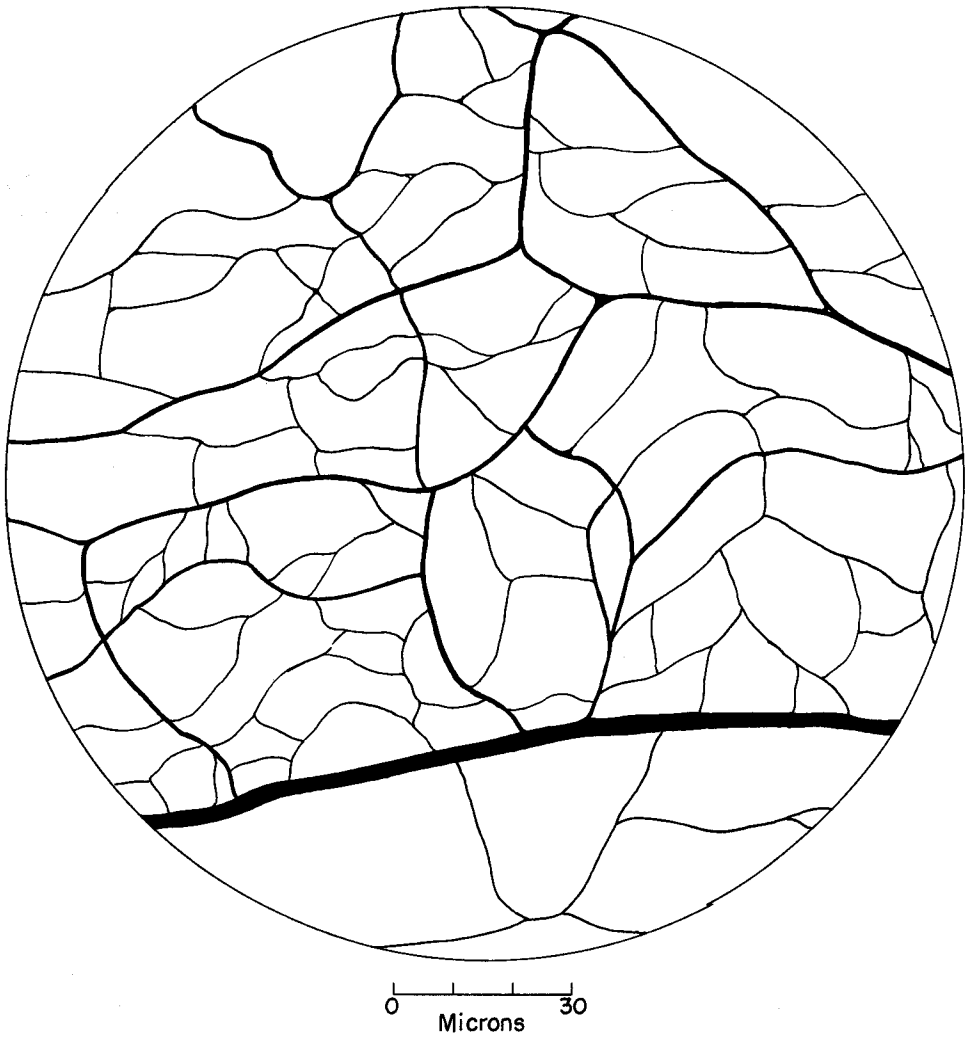

FIGURE 87.—Small area of mantle showing nerve net. Formalin 5 percent, gold impregnation. Whole mount. Camera lucida drawing.

At the very bottom of the groove the tall epithelial cells are suddenly replaced by short cubical cells (fig. 88, right side) which extend a short distance along the inner side of the groove.

The material secreted by the periostracal gland accumulates at the bottom of the groove and in the majority of my preparations appears to adhere to the cells of the outer side (left side of figure 88). This, however, is the result of shrinkage caused by dehydration during the processing of slides. In preparations mounted in glycerin the conchiolin can be seen in close contact with the epithelium of both sides of the groove.

The function of the periostracal gland is to supply large quantities of the material required for new shell growth at the edge of the valves. The organic matrix (conchiolin) and foliated layers of calcite needed for increasing thickness of the valves, on the other hand, are secreted by the epithelium covering the entire outer surface of the mantle and in close contact with the inner surface of the valve. The epithelium consists of nonciliated cells which are cylindrical near the free margin of the mantle but become flattened and almost cubical in more proximal areas. Both conchiolin-secreting and calcium-secreting cells are present in this epithelium but their cytological differentiation by means of staining reactions or by precipitation of calcium oxalate is not reliable. Mucus cells and oval cells containing eosinophile granules also occur throughout the entire surface of the epithelial covering.

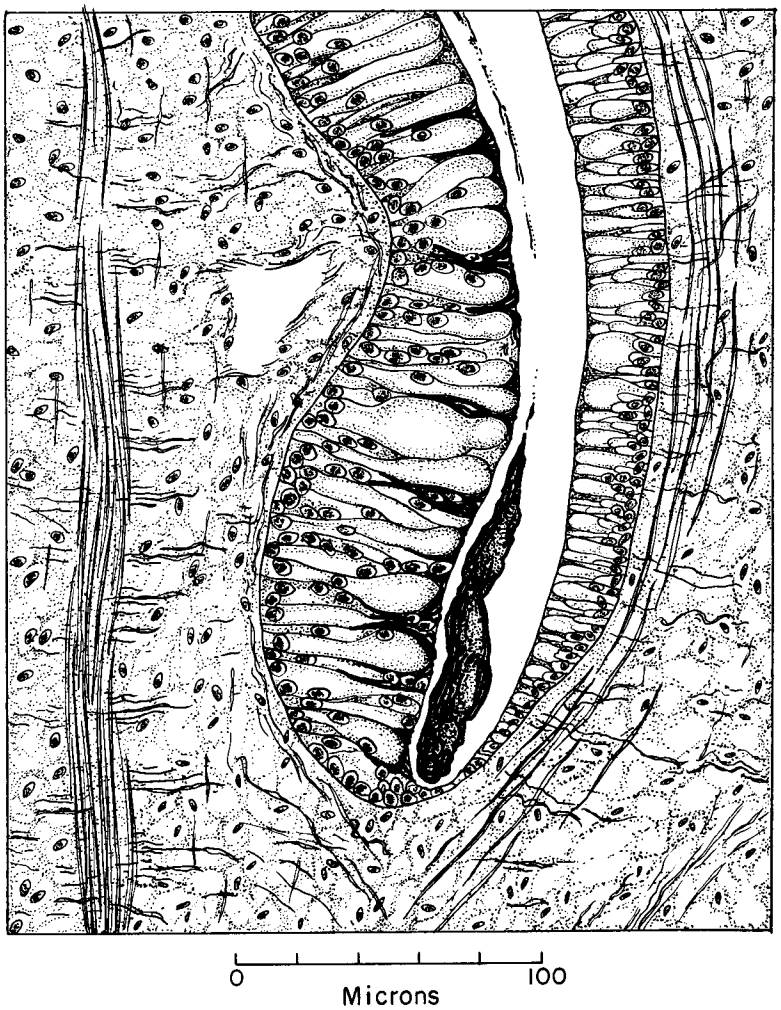

FIGURE 88.—Transverse section of the periostracal groove. The cells on the left side are distended with secretion; those at the very bottom are short, almost cuboid. The black mass at the bottom of the groove is conchiolin. Bouin, hematoxylin-eosin.

Owing to the presence of the conchiolin-secreting cells, the entire outer surface of the mantle is sticky and adheres closely to the inner surface of the shell. List (1902) advanced a theory, not well supported by observation, that in the Mytilidae the mantle adheres to the shell by means of fibrillae which originate in the myoepithelial cells and pass through the epithelium. Such an arrangement is not found in *C. virginica* or in *C. angulata*, and according to Leenhardt (1926) does not exist in *Mytilus*.

The epithelial layer along both surfaces of the mantle including its free edge contains alkaline phosphatase, an enzyme involved in the calcification of the shell. The presence of the enzyme can be demonstrated by the Gomori method (Gomori, 1939, 1943) based on the formation of insoluble calcium phosphate as a result of phosphatase action on sodium glycero-phosphate and calcium ions. Further treatment with 5 percent silver nitrate (or with cobalt nitrate) converts the calcium phosphate to silver (or cobalt) phosphate which turns black after exposure to light. Both reagents gave satisfactory results in demonstrating the localization of the enzyme in the epithelium of the mantle. The strongest reaction, judged by the opacity and width of the black layer, was found to occur along the edges of the mantle and in the area of the periostracal groove. Even the tips of the tentacles contained noticeable amounts of the enzyme (fig. 89). These obser-